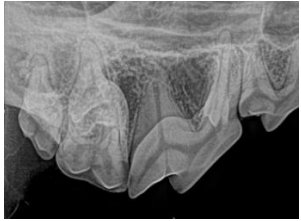


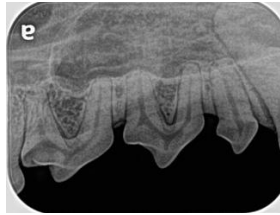
Canine Full-Mouth Radiographic Series

Right

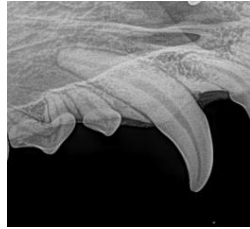
Left



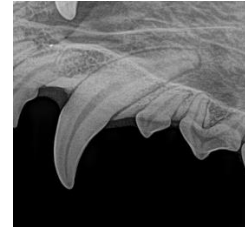
Intraoral bisecting angle
108, 109, 110



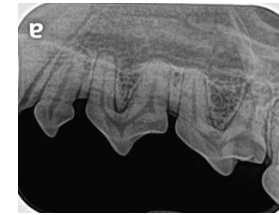
Intraoral bisecting angle
105, 106, 107



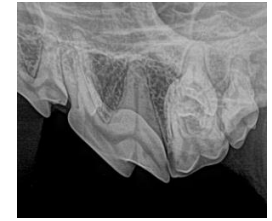
Intraoral bisecting angle 104



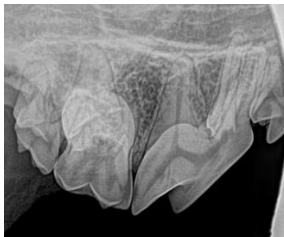
Intraoral bisecting angle 204



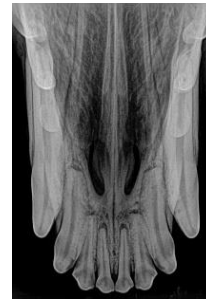Intraoral bisecting angle
205, 206, 207



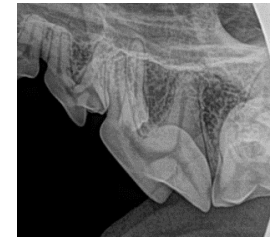Intraoral bisecting angle
208, 209, 210



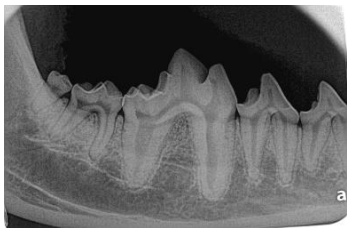108 mesial root separation



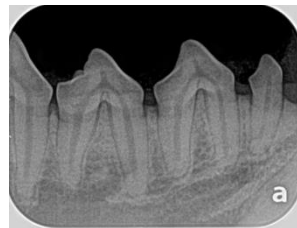Intraoral bisecting angle
101, 102, 103, 201, 202, 203



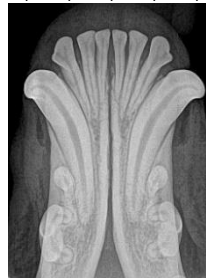208 mesial root separation



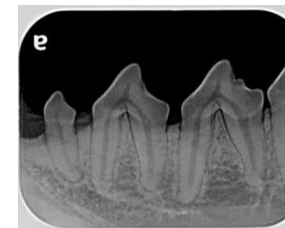
Intraoral parallel
408, 409, 410, 411



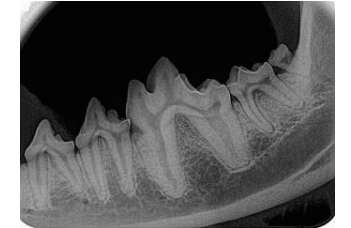Intraoral bisecting angle
405, 406, 407



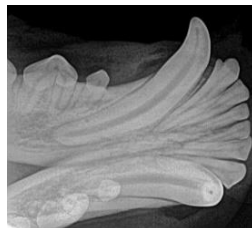
Intraoral bisecting angle
301, 302, 303, 304,
401, 402, 403, 404



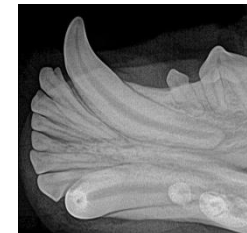
Intraoral bisecting angle
305, 306, 307



Intraoral parallel
307, 308, 309, 310, 311



Intraoral bisecting angle 404



Intraoral bisecting angle 304