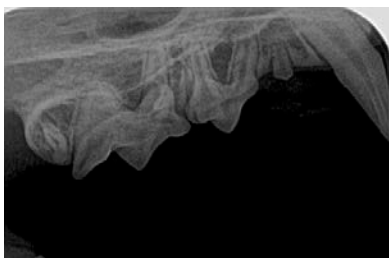


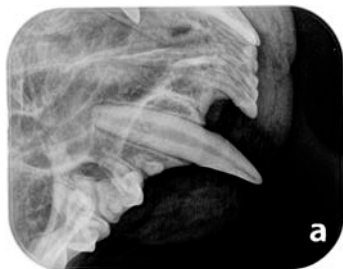# Feline Intraoral Full-Mouth Radiographic Series.

**RIGHT**

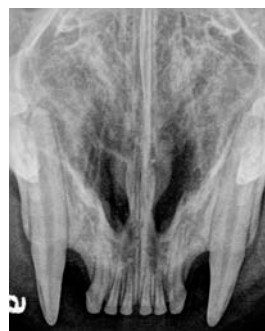**LEFT**



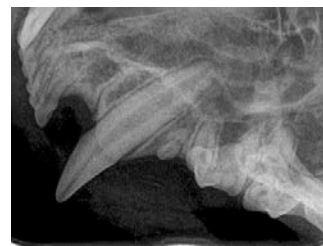Lateral Near Parallel Technique  
109, 108, 107, 106



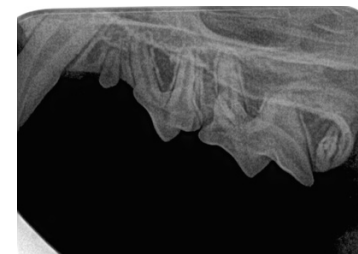Lateral Bisecting Angle 104



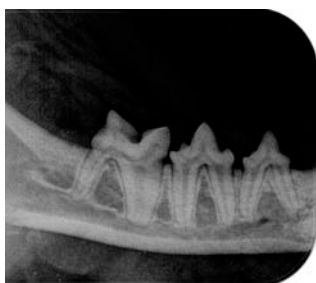Occlusal Bisecting Angle  
104, 103, 102, 101, 201, 202, 203, 204



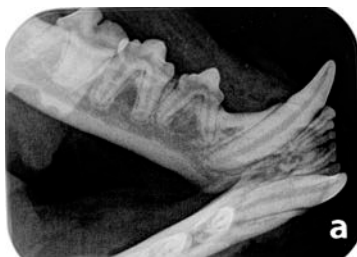Lateral Bisecting Angle 204



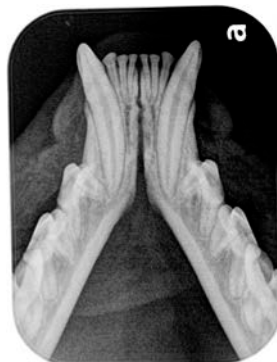Lateral Near Parallel Technique  
206, 207, 208, 209



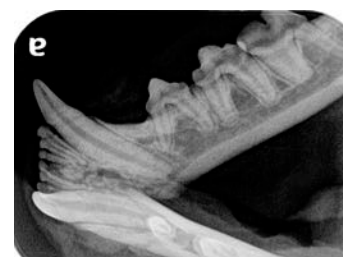Lateral Parallel Technique  
409, 408, 407



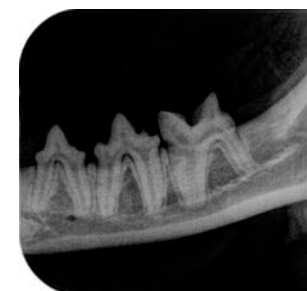
Lateral Bisecting Angle 404



Occlusal Bisecting Angle  
404, 403, 402, 401, 301, 302, 303, 304



Lateral Bisecting Angle 304



Lateral Parallel Technique  
307, 308, 309